

# Microfocused Ultrasound for Skin Tightening

Jennifer L. MacGregor, MD,\* and Elizabeth L. Tanzi, MD†

The demand for noninvasive skin tightening procedures is increasing as patients seek safe and effective alternatives to aesthetic surgical procedures of the face, neck, and body. Over the past decade, radiofrequency and infrared laser devices have been popularized owing to their ability to deliver controlled heat to the dermis, stimulate neocollagenesis, and effect modest tissue tightening with minimal recovery. However, these less invasive approaches are historically associated with inferior efficacy so that surgery still remains the treatment of choice to address moderate to severe tissue laxity. Microfocused ultrasound was recently introduced as a novel energy modality for transcutaneous heat delivery that reaches the deeper subdermal connective tissue in tightly focused zones at consistent programmed depths. The goal is to produce a deeper wound healing response at multiple levels with robust collagen remodeling and a more durable clinical response. The Ulthera device (Ulthera, Inc, Meza, AZ), with refined microfocused ultrasound technology, has been adapted specifically for skin tightening and lifting with little recovery or risk of complications since its introduction in 2009. As clinical parameters are studied and optimized, enhanced efficacy and consistency of clinical improvement is expected.

Semin Cutan Med Surg 32:18-25 © 2013 Frontline Medical Communications

**KEYWORDS** microfocused ultrasound, noninvasive skin tightening

Facial and neck skin laxity has traditionally been addressed using surgical lifting techniques. Over the past decade, a wide range of nonsurgical treatments have emerged as an alternative to surgery. Procedures such as radiofrequency (RF) and ablative and fractional laser skin resurfacing provide variable degrees of tissue tightening through the delivery of controlled dermal heating. Although tissue tightening has been shown with these devices, several shortcomings exist, including inconsistent clinical results, extensive recovery requirements after the procedure, and the need for multiple treatment sessions.<sup>1-7</sup> As such, the need for additional noninvasive face and neck rejuvenation procedures with minimal recovery and consistent results that more closely mimic those of traditional surgical techniques continues. In 2009, microfocused ultrasound (MFUS) was introduced to deliver precise focused zones of thermal injury at treatment depths greater than the aforementioned technologies. The MFUS device may be uniquely suited to address the problem

of skin laxity owing to its ability to deliver deep thermal energy at tissue planes in the subdermal connective tissue in addition to the superficial dermis to effect more complete collagen remodeling.

## Evolution of Nonsurgical Technology and Mechanism of Action

Traditional ablative laser skin resurfacing with carbon dioxide or erbium:yttrium-aluminum-garnet devices selectively ablates the epidermis while delivering significant thermal injury to the dermis sufficient to stimulate a robust wound healing response with subsequent collagen remodeling and contraction.<sup>1-3</sup> However, traditional ablative laser skin resurfacing is associated with extensive postoperative recovery and risk of delayed dyspigmentation.<sup>4</sup> Modest skin tightening can also be induced by RF devices that rely on heat delivery up to 2-4 mm into the dermis to stimulate the wound healing cascade and neocollagenesis without epidermal injury and associated clinical recovery.<sup>5-7</sup> The benefits of this approach are clear—limited downtime, relative safety for use on nonfacial areas and skin of color, and a favorable side effect profile as compared with ablative laser skin resurfacing or surgical lifting procedures. Unfortunately, less invasive

\*Union Square Laser Dermatology, Columbia University Medical Center, New York, NY.

†Washington Institute of Dermatologic Laser Surgery, Washington, DC.

Disclosures: The authors have completed and submitted the ICMJE form for disclosure of potential conflicts of interest and none were reported.

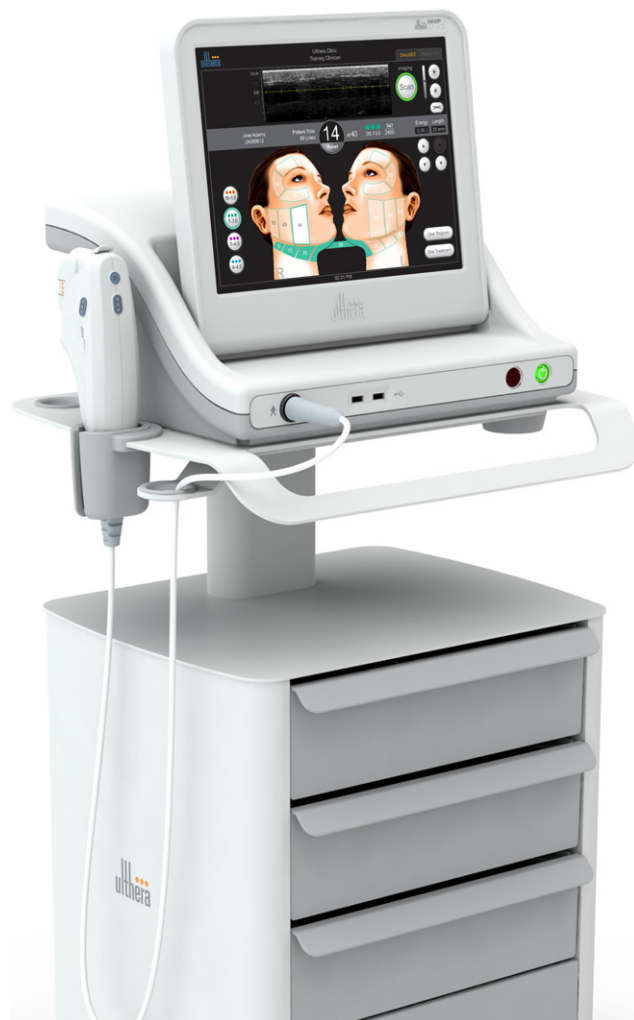Correspondence: Elizabeth L. Tanzi, MD, Washington Institute of Dermatologic Laser Surgery, 1430 K Street, NW, Suite 200, Washington, DC 20005. E-mail: etanzi@skinlaser.com

approaches are historically associated with inferior efficacy, inconsistent clinical response, and a less durable tightening effect.

High-intensity focused ultrasound (HIFU) acoustic energy, known to propagate much deeper through tissue than laser or RF energy, has been previously investigated for use in bulk heating for the treatments of solid organ tumors<sup>8-10</sup> and recently adapted for the treatment of subcutaneous lipolysis.<sup>11</sup> The ultrasound waves penetrate into tissue, leading to vibration in molecules at the site of beam focus. The friction between tissue molecules produces heat and thermal injury at the focal site of the beam. Penetration depth is determined by frequency in which higher frequency waves produce a shallow focal injury zone and lower frequency waves have a greater depth of penetration to produce focal thermal injury zones (TIZs) at deeper layers. The treatment of solid organ tumors and adipocytes relies on bulk heating over a larger area ( $>1\text{ cm}^3$ ) to accomplish tissue destruction through thermal effects and the cavitation process. In comparison with HIFU, MFUS allows for more precise energy delivery as a result of advances within the system to better address the needs of skin laxity.<sup>12-14</sup> For transcutaneous treatment, modifications of short pulse durations coupled with higher frequency transducers allow MFUS to deliver precise zones of coagulative necrosis, so-called TIZs. Each TIZ is tightly focused at a given depth and heated precisely using shorter pulses ( $<150\text{ ms}$ ) to produce small zones ( $1\text{ mm}^3$ ) of coagulative necrosis at the site with surrounding tissue and superficial layers essentially unaffected.<sup>12-14</sup> Similar to a laser pulse, the thermal injury is confined by keeping the pulse duration relatively short. The epidermal surface remains unaffected as long as the energy delivered is not excessive for the given focal depth and frequency emitted by a given transducer, eliminating the need for superficial cooling and speeding the recovery process, as healing occurs rapidly from untreated adjacent tissue.<sup>13,14</sup>

The MFUS device is able to penetrate deeper into tissue than its nonsurgical predecessors in an effort to affect superior tissue tightening and longevity of results by selectively targeting the superficial musculoaponeurotic system (SMAS). The SMAS lies deep to the subcutaneous fat, envelops the muscles of facial expression, and extends superficially to connect with the dermis.<sup>15</sup> The SMAS layer is composed of collagen and elastic fibers similar to the dermal layer of the skin; however, it has more durable holding property and less delayed relaxation after lifting procedures than skin alone.<sup>15</sup> Thus, the SMAS is a desirable target for noninvasive skin tightening procedures.

The Ulthera device (Ulthera, Inc, Meza, AZ) has refined MFUS technology using transducer handpieces uniquely capable of imaging mode (lower energy ultrasound for real-time imaging) and treatment mode (delivery of higher energy ultrasound exposures [Fig. 1]). The energy is delivered in a straight 2.5-cm line with TIZs 0.5-5 mm apart at a given depth within the tissue. Short pulse durations (25-50 ms) and relatively low energy (0.4-1.2 J, range depending on the transducer) confine the TIZs to their intended depth. The transducers are fixed at 7.5 MHz (3 and 4.5 mm focal depths)

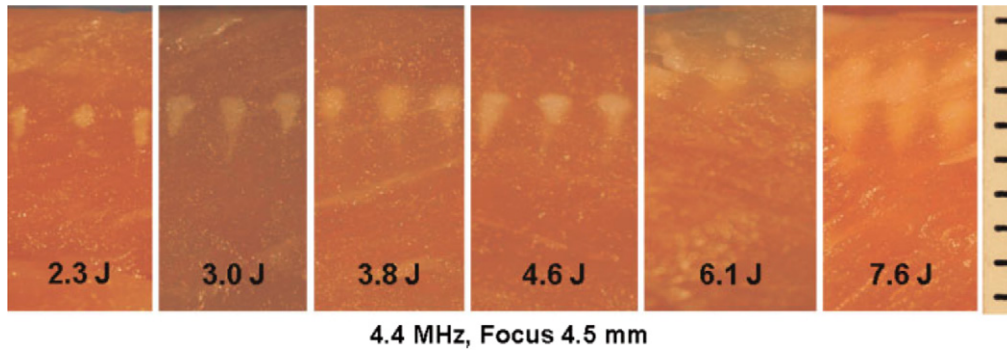


**Figure 1** Ulthera microfocused ultrasound device.

and 4.4 MHz (4.5 mm focal depth) frequencies. Most recently, a 19-MHz transducer capable of delivering TIZ at depths of 1.5 mm into the dermis was introduced to effect more superficial dermal neocollagenesis. Preclinical studies in cadaver, porcine, and prerhytidectomy excision skin have confirmed consistency in the depth, size, and orientation of TIZ created by MFUS in the deep dermis and SMAS (Fig. 2).<sup>12-14,16</sup>

## Clinical Use for Skin Tightening

Early clinical and preclinical work led to Food and Drug Administration approval of the MFUS device in 2009 for eyebrow lifting. Eyebrow lifting is straightforward to measure using standardized photography, whereas lower face and neck tightening are more difficult to quantify, given the lack of an established and objective grading scale for evaluation of improvement.<sup>17,18</sup> Early studies quantify lower face and neck tightening with a subjective rating of “improved” reported by patient self-assessment and blinded physicians.<sup>19,20</sup> However, subsequent studies and off-label use in the lower face and neck that yielded consistent results led to a Food and



**Figure 2** Geometry of thermal injury zones in porcine muscle as delivered energy is increased from 2.3 to 7.6 J. The inverse cone-shaped lesions demonstrate consistent size, depth, and spacing of coagulative necrosis. (Reprinted from White, et al.,<sup>12</sup> with permission, Wiley Periodicals.)

Drug Administration approved indication for “noninvasive lift of lax tissue of the neck and submentum” in 2012.<sup>21</sup>

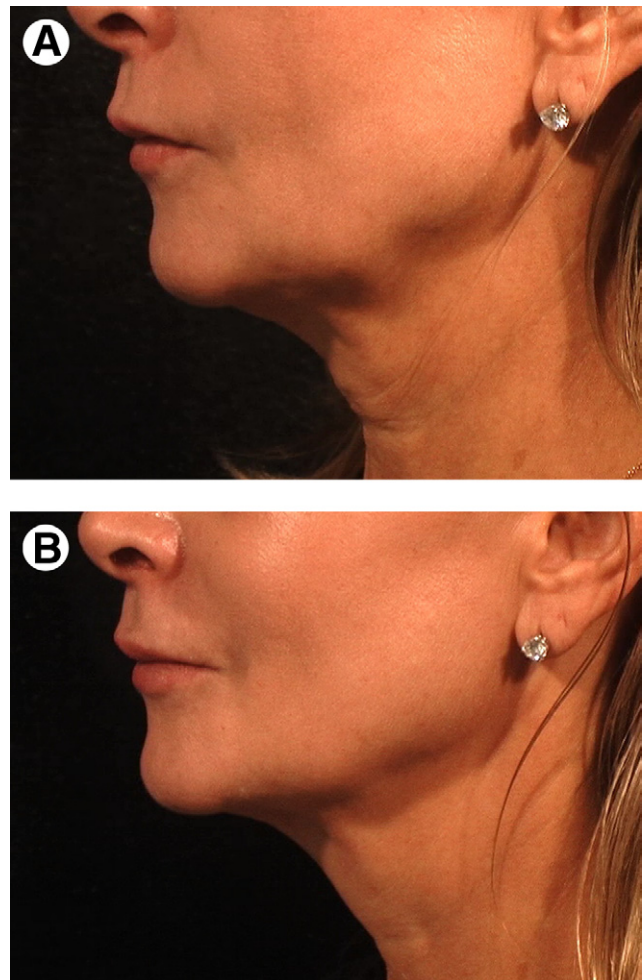Alam et al<sup>17</sup> conducted the first clinical study of full-face and neck MFUS treatment in 35 patients, looking at safety and efficacy. In standardized photographs, 86% of the patients achieved significant improvement as measured by blinded physician assessment. Photographic measurements demonstrated a mean brow lift of 1.7 mm.

Chan et al<sup>22</sup> evaluated the safety of MFUS skin tightening in 49 Chinese patients using an advanced protocol. All patients underwent full-facial and neck treatment without significant or persistent adverse effects. Suh et al<sup>19</sup> evaluated 22 Korean patients after full-face treatment and reported 91% of patients improved, as rated on a subjective scale where 1 = improved and 2 = much improved at the nasolabial fold and jaw line (1.77 and 1.72 average improvement, respectively). Skin biopsies obtained from 11 study subjects at baseline and 2 months after treatment confirmed an increase in reticular dermal collagen and dermal thickening, with elastic fibers appearing more parallel and straighter than pretreatment specimens.<sup>19</sup> Lee et al<sup>20</sup> reported subjective improvement in 9 of 10 patients by their own self-assessment, and 8 of 10 patients were rated as “improved” by blinded physician assessment. Suh et al<sup>23</sup> subsequently showed subjective improvement in most patients treated with a single pass to the lower infraorbital region in 15 patients treated with a 7-MHz 3-mm transducer.

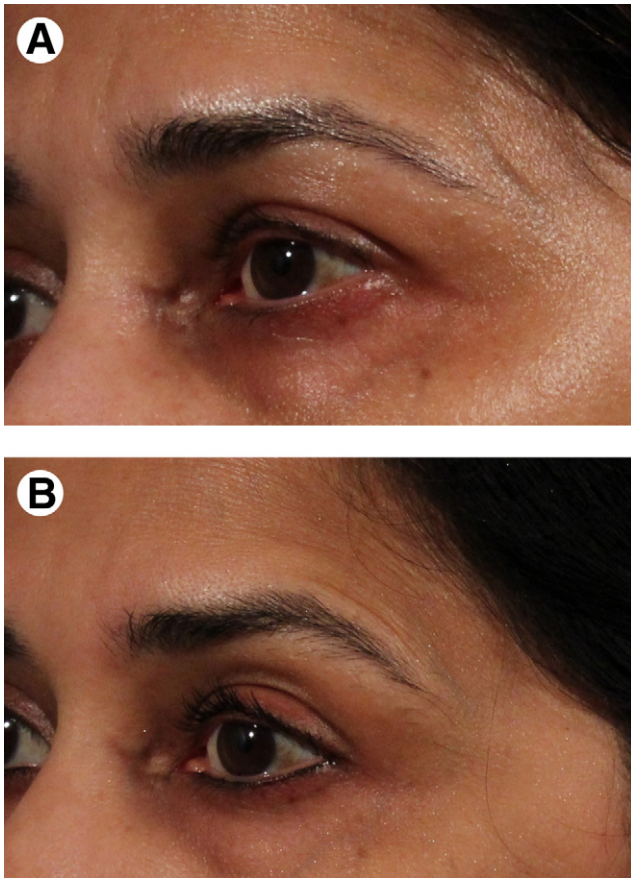
Alster and Tanzi<sup>24</sup> established the first report of clinical efficacy in nonfacial areas. Paired sites in 18 women were evaluated on the arms, knees, or medial thighs where dual-plane treatment with the 4-MHz 4.5-mm-depth and 7-MHz 3-mm-depth transducer was compared with single-plane treatment with the 4-MHz 4.5-mm-depth transducer alone. Global assessment scores of skin tightening and lifting were determined by 2 blinded physician raters and graded using a quartile grading scale. At the 6-month follow-up visit, statistically significant improvement was seen at all 3 body sites, with the arms and knees demonstrating more noticeable improvement than thighs. Dual-plane treatment yielded additional benefit in smoothing skin texture, an effect potentially related to more superficial dermal collagen remodeling. When asked to rate their impression of clinical efficacy, 13 of

16 patients reported being “highly satisfied” with the treatment.

Sasaki and Tevez<sup>21,25</sup> have reported on their extensive experience with the use of MFUS for multiple indications. Using the new 19-MHz 1.5-mm superficial transducer, they treated 19 patients in the periorbital region with 45 lines on each side, with another 45 lines using the 7-MHz 3-mm as



**Figure 3** Neck before (A) and 6 months after (B) a single microfocused ultrasound treatment of the cheeks and neck.



**Figure 4** Periorbital area before (A) and 6 months after (B) a single microfocused ultrasound treatment of the brow.

the second depth over the orbital rim.<sup>25</sup> Brow elevation was measured between 1 and 2 mm in each of 19 patients treated, and periorbital skin tightening was rated as moderate between a 3- and 6-month period. Body sites treated in this study included décolletage (5), brachium (44), periumbilicus (6), inner thigh (1), knee (4), hand (1), and buttocks (2). Treatment protocols varied according to skin thickness at the target site. Blinded evaluator assessment scores revealed moderate improvement in the periorbital area, inner brachium, periumbilicus, and knees. Less consistent results were achieved in the décolletage, inner thighs, hands, and buttocks. In a larger series of pilot studies and clinical investigations, the authors compared horizontal and vertical vectors in the brow and marionette regions while keeping depth and energy constant.<sup>21</sup> Vertical vectors were superior in all sites and energy settings evaluated. They also evaluated a

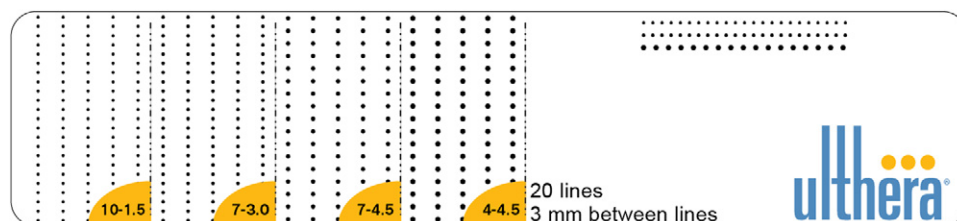
larger number of patients to confirm that a higher number of lines and joules would yield significantly superior results at all areas treated. In total, 193 patients were included in the investigations.<sup>21</sup>

Recent presentations at scientific meetings have included additional data supporting efficacy for MFUS treatment of wrinkling around the knee,<sup>26</sup> tightening of the neck,<sup>27</sup> décolletage,<sup>28</sup> and buttock,<sup>29</sup> and the potential to treat axillary hyperhidrosis.<sup>30</sup> Future directions of research include its potential to induce scar remodeling, which would be particularly useful in deep or contracted scars. MFUS has also been reported to soften silicone and associated scarring of the lip.<sup>31</sup> The potential for anti-inflammatory effect and possible use in acneiform disorders is also a current subject of investigation.

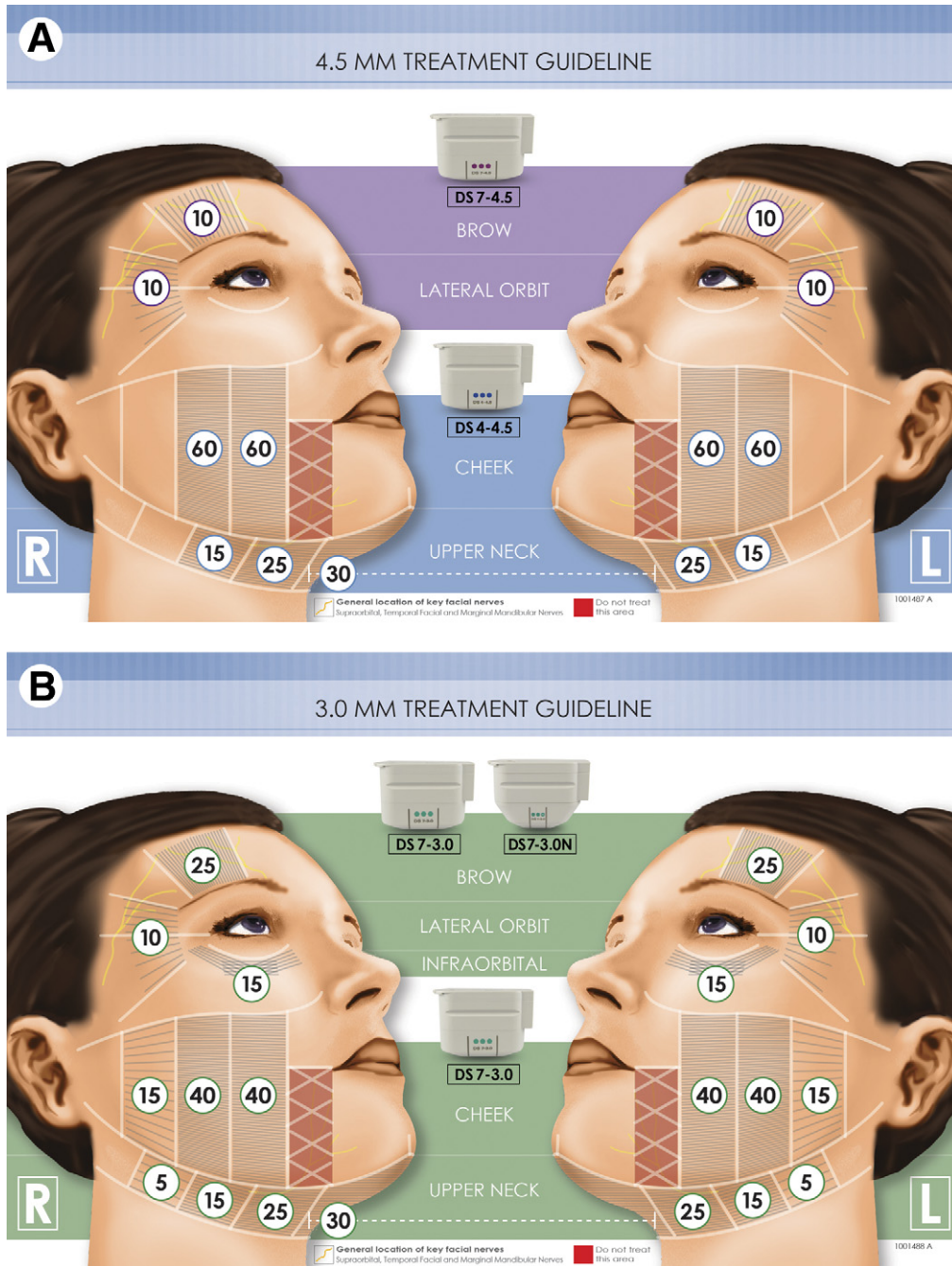
## Patient Selection and Preparation

The ideal patient for nonsurgical tissue tightening displays mild to moderate skin and soft tissue laxity (Figs. 3 and 4). Severe skin laxity, marked platysmal banding, severe jowling, and low cervicomental angle are problems best addressed by surgical interventions. In the authors' experience, younger patients are more likely to have a good outcome with MFUS, as the wound healing response to thermal injury is vigorous. By contrast, patients with excessively photodamaged skin or a history of smoking are less favorable candidates, as their ability to create collagen in response to thermal injury may be inadequate. The few absolute contraindications include active infection or open skin at the treatment site, cystic acne, and pregnancy. Relative contraindications include medical conditions and medications that alter or impair wound healing.

Another relative contraindication to MFUS skin tightening is the patient with unrealistic expectations of treatment. The overall rate of nonresponse in current published clinical studies is <20%, with the clear advantage of MFUS being a safe and effective alternative to surgical lifting or ablative laser resurfacing with minimal to no recovery. However, clinical improvements are often subtle and do not approach those of surgical lifting procedures. Indeed, modest tightening may be satisfactory for 1 patient, whereas similar improvement would leave another dissatisfied with the procedure. Therefore, before treatment, high-quality medical photographs must be obtained and used in conjunction with a candid physician–patient discussion that includes realistic expecta-



**Figure 5** Card for preoperative planning of line placement and marking.



**Figure 6** Diagram of dual-plane treatment guidelines. Treatment suggestions for a deep 4.5-mm focal depth transducer (A) followed by a superficial 3.0-mm focal depth superficial transducer (B). (Reprinted from Ulthera treatment guidelines, Ulthera, Mesa, AZ; with permission.)

tions of improvement, maintenance requirements, limitations in achieving the patient's goal of "lifting" the tissues without surgery, and the possibility of no appreciable clinical improvement.

As with any heat-based cosmetic procedure, there are variable degrees of discomfort associated with MFUS skin tightening. Preoperative planning should include a discussion of the patient's historical pain tolerance and response to anxiolytic and narcotic pain medications. Individual published reports of pain in response to the treatment range from mild to severe. Sufficient pain management is critical to an effective

outcome and the overall treatment experience for the patient. As such, the authors use a combination of oral anxiolytics (5-10 mg of diazepam) and intramuscular narcotics (50-75 mg of IM meperidine) 20-30 minutes before treatment to alleviate discomfort in most patients. Other methods of pain management have been described, including high-dose nonsteroidal anti-inflammatory drugs, oral or intravenous narcotics, topical or local injections of anesthetics, conscious sedation, and cold techniques.<sup>32</sup> The deeper probe and higher energy delivery is associated with increased pain. For superficial treatment of periorcular and perioral rhytides us-

**Table 1** Complications of Microfocused Ultrasound

Mild/Transient	Moderate	Severe/ Prolonged
Erythema	Transient dysesthesia	None reported
Purpura	Motor nerve paresis	
Postinflammatory hyperpigmentation		
Geometrical wheals or striations		
Subcutaneous nodules		
Edema		

ing the 1.5-mm-depth transducer, topical anesthesia alone may effectively lessen treatment-associated discomfort.

## Operative Technique

Four transducers are available for transcutaneous treatment using the MFUS device. These interchangeable dual-functioning transducers are labeled according to their frequency and focal treatment depth. They include 4-MHz 4.5-mm focal depth (0.75-1.2 J), 7-MHz 4.5-mm focal depth (0.75-1.05 J), 7-MHz 3-mm focal depth (0.4-0.63 J), and 19-MHz 1.5-mm focal depth (0.15-0.25 J). In general, the areas with the thinnest skin, such as the neck and periocular area, should be treated with superficial depth probes; the brow and temple should be treated with superficial and deeper probes; and cheek and submental skin is best treated with the deepest 4-MHz 4.5-mm probe followed by additional treatment with a superficial probe. Multiple treatment protocols using single-, double-, and even triple-depth treatment planes have been reported, and the parameters continue to be refined in different treatment protocols to enhance efficacy. The technique of layering multiple depths of TIZs throughout the treatment area enhances efficacy in both facial and nonfacial treatment sites.<sup>21,24,25</sup>

Before treatment, the skin is freshly cleansed, dried, and cleared free of makeup, sunscreen, or products. Each tar-

geted region for treatment is outlined with a planning card to determine the number of treatment columns required to deliver energy with minimal overlap (Fig. 5). Ultrasound gel is applied to the skin, and the probe is placed firmly and gently on the target site so the entire transducer is evenly coupled to the skin surface. Correct technique is confirmed with visualization of acoustic coupling as seen on the ultrasound images on the monitor. Focal depth is visible on the screen in the corresponding ultrasound image and lined up with the deep dermis to SMAS, depending on the transducer and targeted site. Treatment lines of ultrasound pulses are manually delivered adjacent and parallel to one another with minimal spacing (<3 mm). The overall number of lines placed in a treatment area will depend on the size of the treatment area and chosen protocol (Fig. 6). The most advanced protocols call for the placement of 600-800 lines of ultrasound pulses when treating the full face. Until additional experience with a large cohort of patients confirms its safety, treatment over soft tissue augmentation material and implants should be approached with caution. Because there are no commercially available eye shields known to prevent propagation of ultrasound energy over the globe, treatment inside the orbital rim is not possible. The thyroid gland is palpated and marked before treatment to avoid inadvertent delivery of ultrasound pulses over the area.

## Postoperative Management, Side Effects, and Complications

After treatment, ultrasound gel is removed and a bland moisturizer applied. Patients are instructed to care for their skin as they normally would with no restrictions on activity. If systemic pain management was used, the patient is discharged with appropriate transportation. If desired, the patient may apply cold compresses to the treatment area in the hours after the procedure to minimize local edema; however, its use is not mandatory in all patients, as degrees of swelling after treatment are variable.

Noninvasive skin tightening with MFUS produces relatively few expected side effects and transient complications (Table 1). Post-treatment erythema is expected in most patients and typically resolves in the first few hours to days.

**Table 2** Prevention of Complications From Microfocused Ultrasound

Motor nerve paresis	Ask patient to report any facial muscle twitching during treatment near superficial motor nerves and apply ice to any red or inflamed areas after treatment
Forehead palsy	Avoid treatment over the temporal branch of the trigeminal nerve
Perioral palsy	Avoid treatment over the marginal mandibular nerve
Nodules	Use appropriate treatment density and technique as confirmed by corresponding ultrasound image on monitor
Bruising	Avoid treating patients on blood thinning medications and administering pulse directly to a visible vessel on the ultrasound image
White striations or geometrical wheals	Typically occur with superficial transducer—ensure proper coupling with corresponding ultrasound image before each pulse delivery



**Figure 7** Diagram of proper distribution of line placement and “danger zones” over relative location of temporal branch of trigeminal and marginal mandibular nerves.

Small areas of purpura may develop and are expected to resolve over 1-2 weeks. Linear or geometrical striations seen after treatment with the superficial transducer are treated with topical corticosteroids and followed for rapid resolution.<sup>17,19,21</sup> No permanent textural changes from these lesions have been reported. Lingering mild to moderate skin tenderness and edema in the first 1-4 weeks after treatment is common.<sup>22,24</sup> Transient postinflammatory pigmentation was observed in 2 Chinese patients treated over the brow, but was most likely related to placement of the deep 4-MHz 4.5-mm transducer and was not observed in subsequent treatments.<sup>22</sup> Focal areas of numbness on the brow or perioral area can occur with return of full sensation within several weeks without intervention.<sup>19,21,22</sup>

Although uncommon, more serious complications after MFUS skin tightening can occur, including the development of palpable subcutaneous nodules and/or motor nerve paresis.<sup>33</sup> Fortunately, these effects are temporary and can be avoided with proper operative technique (Table 2). Motor nerve paresis is the most concerning potential complication in the immediate post-treatment period, and its incidence is limited to case reports. The areas at the greatest risk for injury are the temporal branch of the trigeminal nerve as well as the marginal mandibular nerve, where the course of the nerve becomes relatively superficial (Fig. 7). The affected patient will present with an inability to contract the frontalis muscle or perioral asymmetry. Symptoms usually occur within the first 1-12 hours after treatment and are likely related to nerve inflammation. Resolution is expected in 2-6 weeks, and no permanent nerve injury has been reported to date.<sup>33</sup> For pa-

tients who notice facial muscle twitching during treatment near “danger zone” regions, ice should be immediately applied and anti-inflammatory medication considered.

## Conclusions

MFUS is capable of delivering transcutaneous ultrasound energy to selectively heat dermal and subdermal tissues in a linear array of tightly focused TIZs. As superficial and surrounding tissue is unaffected, rapid clinical recovery is coupled with a favorable side effect profile. Initiation of the wound healing response with subsequent neocollagenesis and tissue contraction leads to gradual lifting and tightening of the skin. As clinical parameters are studied and optimized, enhanced efficacy and consistency of clinical improvement is expected. Future applications and current areas of investigation for MFUS include the targeting of adnexal structures for acne, rosacea, and hyperhidrosis, as well as expanded use for nonfacial skin tightening.

## References

- Ross EV, McKinlay JR, Anderson RR. Why does carbon dioxide resurfacing work? A review. *Arch Dermatol.* 1999;135:444-454.
- Ross EV, Naseef GS, McKinlay JR, et al. Comparison of carbon dioxide laser, erbium:YAG laser, dermabrasion and dermatome: A study of thermal damage, wound contraction and wound healing in a live pig model: Implications for skin resurfacing. *J Am Acad Dermatol.* 2000;42:92-105.
- Fitzpatrick RE, Rostan EF, Marchell N. Collagen tightening induced by carbon dioxide laser versus erbium:YAG laser. *Lasers Surg Med.* 2000;27:395-403.
- Tanzi EL, Lupton JR, Alster TS. Lasers in dermatology: Four decades of progress. *J Am Acad Dermatol.* 2003;49:1-31.
- Alster TS, Tanzi E. Improvement of neck and cheek laxity with a nonablative radiofrequency device: A lifting experience. *Dermatol Surg.* 2004;30:503-507.
- Zelickson BD, Kist D, Bernstein E, et al. Histological and ultrastructural evaluation of the effects of a radiofrequency-based nonablative dermal remodeling device: A pilot study. *Arch Dermatol.* 2004;140:204-209.
- Arnoczky SP, Aksan A. Thermal modification of connective tissues: Basic science considerations and clinical implications. *J Am Acad Orthop Surg.* 2000;8:305-313.
- Kennedy JE, ter Haar GR, Cranston D. High intensity focused ultrasound: Surgery of the future? *Br J Radiol.* 2003;76:590-599.
- Mast TD, Makin IR, Faidi W, et al. Bulk ablation of soft tissue with intense ultrasound (IUS): Modeling and experiments. *J Acoust Soc Am.* 2005;118:2715-2724.
- Van Leenders GJ, Beerlage HP, Ruijter ET, et al. Histopathological changes associated with high intensity focused ultrasound (HIFU) treatment for localised adenocarcinoma of the prostate. *J Clin Pathol.* 2000;53:391-394.
- Fatemi A. High-intensity focused ultrasound effectively reduces adipose tissue. *Semin Cutan Med Surg.* 2009;28:257-262.
- White WM, Makin IR, Slayton MH, et al. Selective transcutaneous delivery of energy to porcine soft tissues using intense ultrasound (IUS). *Lasers Surg Med.* 2008;40:67-75.
- White WM, Makin IR, Barthe PG, et al. Selective creation of thermal injury zones in the superficial musculoaponeurotic system using intense ultrasound therapy: A new target for noninvasive facial rejuvenation. *Arch Facial Plast Surg.* 2007;9:22-29.
- Laubach HJ, Makin IR, Barthe PG, et al. Intense focused ultrasound: Evaluation of a new treatment modality for precise microcoagulation within the skin. *Dermatol Surg.* 2008;34:727-734.
- Har-Shai Y, Bodner SR, Egozy-Golan D, et al. Mechanical properties

- and microstructure of the superficial musculoaponeurotic system. *Plast Reconstr Surg*. 1996;98:59-70.
16. Gliklich RE, White WM, Slayton MH, et al. Clinical pilot study of intense ultrasound therapy to deep dermal facial skin and subcutaneous tissues. *Arch Facial Plast Surg*. 2007;9:88-95.
  17. Alam M, White LE, Martin N, et al. Ultrasound tightening of facial and neck skin: A rater-blinded prospective cohort study. *J Am Acad Dermatol*. 2010;62:262-269.
  18. Weiss M. Commentary: Noninvasive skin tightening: Ultrasound and other technologies: Where are we in 2011? *Dermatol Surg*. 2012;38:28-30.
  19. Suh DH, Shin MK, Lee SJ, et al. Intense focused ultrasound tightening in Asian skin: Clinical and pathologic results. *Dermatol Surg*. 2011;37:1595-1602.
  20. Lee HS, Jang WS, Cha YJ, et al. Multiple pass ultrasound tightening of skin laxity of the lower face and neck. *Dermatol Surg*. 2012;38:20-27.
  21. Sasaki GH, Tevez A. Clinical efficacy and safety of focused-image ultrasonography: A 2-year experience. *Aesthet Surg J*. 2012;32:601-612.
  22. Chan NP, Shek SY, Yu CS, et al. Safety study of transcutaneous focused ultrasound for non-invasive skin tightening in Asians. *Lasers Surg Med*. 2011;43:366-375.
  23. Suh DH, Oh YJ, Lee SJ, et al. Intense focused ultrasound tightening for the treatment of infraorbital laxity. *J Cosmet Laser Ther*. 2012;14:290-295.
  24. Alster TS, Tanzi EL. Noninvasive lifting of arm, thigh, and knee skin with transcutaneous intense focused ultrasound. *Dermatol Surg*. 2012;38:754-759.
  25. Sasaki GH, Tevez A. Microfocused ultrasound for nonablative skin and subdermal tightening to the periorbitum and body sites: Preliminary report on eighty-two patients. *J Cosmet Dermatol Sci Appl*. 2012;2:108-116.
  26. Gold MH. Ulthera—A single center, prospective study on the efficacy of the micro-focused ultrasound for the non-invasive treatment of skin wrinkles above the knee. Data Presented at the American Society for Dermatologic Surgery Meeting, Atlanta, GA, 2012.
  27. Elm KDL, Schram SE, Wallander ID, et al. Evaluation of a high intensity focused ultrasound system for lifting and tightening of the neck. Data Presented at the American Society for Dermatologic Surgery Meeting, Atlanta, GA, 2012.
  28. Fabi SG, Massaki A, Goldman M. Evaluation of the micro-focused ultrasound system for lifting and tightening of the décolletage. Data Presented at the American Society for Dermatologic Surgery Meeting, Atlanta, GA, 2012.
  29. Goldberg D, Al-Dujaili Z. Micro-focused ultrasound for lifting and tightening skin laxity of the buttock. Data Presented at the American Society for Dermatologic Surgery Meeting Atlanta, GA, 2012.
  30. Nestor MS. Micro-focused ultrasound for the treatment of axillary hyperhidrosis. Data Presented at the American Society for Dermatologic Surgery Meeting, Atlanta, GA, 2012.
  31. Kornstein AN. Ulthera for silicone lip correction. *Plast Reconstr Surg*. 2012;129:1014e-1015e.
  32. Brobst RW, Ferguson M, Perkins SW. Ulthera: Initial and six month results. *Facial Plast Surg Clin North Am*. 2012;20:163-176.
  33. Missel L. Prevention of potential adverse events associated with use of Ulthera device. *Tech Bull*, 2011.